

Update on Bone Morphogenetic Proteins and Their Application in Spine Surgery

Dino Samartzis, BS, Dip EBHC, Nitin Khanna, MD, Francis H Shen, MD, Howard S An, MD

Bone is a metabolic and dynamic tissue. Such tissue is regularly implemented during operative treatment in various skeletal components to stabilize or restore function and structure through a process called bone fusion. Spinal fusion is a commonly performed procedure used to align and stabilize the axial skeleton.

Spinal fusion was first reported in 1911 by Albee,¹ based on his efforts to inhibit the extension of tuberculosis by using bone harvested from the tibia to provide mechanical support and stability to the spine. That same year, Hibbs² also noted the use of fusion to retard the progression of scoliotic deformity. Since then, spinal fusion has gained immense popularity. In the United States, the use of bone grafts has become so frequent^{3,4} that bone in humans is considered the second most transplanted tissue.⁵ Although a solid bone fusion can afford longterm stability at the motion segment, its prowess is at times hindered by local and systemic factors that often contribute to nonunion and associated morbidities.⁶⁻¹⁸

Approximately 250,000 bone graft procedures are performed each year for spinal fusion.¹⁹ Because nonunion and donor-site morbidity are significant, constant concerns, the search for the ideal graft source is under continuous investigation. As such, autograft has long been considered the gold standard for graft material. Autograft does not carry the risk of transmissible disease, it is biomechanically stable, and it is a highly osteoinductive graft substrate. But disadvantages of this material include increased operative time, deep infection, vas-

cular injury, chronic pain, fracture, increased use of anesthetic, hypersensitivity, cosmesis, gait abnormalities, and insufficient quantity.²⁰⁻²⁵ Even as the gold standard, nonunion rates in the literature for autograft range between 5% and 45%.^{26,27}

Alternatively, allograft is used to avoid morbidities often associated with autograft. Allograft is available in increased quantity and avoids donor-site morbidity. Certain disadvantages also exist with allograft material, such as delayed time to fusion, increased rate of nonunion, delayed or incomplete graft incorporation because of an immune response elicited by the graft, transmission of infection, poor osteoinductive capabilities, and less osteogenic competence as compared with autograft.²⁸⁻³¹ Nevertheless, proper graft processing and preservation techniques are influential in decreasing immunogenicity and maintaining optimal osteoconductive and osteoinductive aptitude of allograft.

Selection of proper bone-graft substrate is essential to achieve successful fusion. The ideal bone graft is characterized by its osteoconductive and osteoinductive capabilities (Table 1), freedom from disease, minimal antigenic factors, and biomechanical stability.³² But local mechanical forces influence the structural integrity of the graft. According to Wolff's laws, bone responds and adapts to structural forces.³³ Compressive and tensile forces are required for proper bone remodeling. Bone formation is optimized under compressive stress and reabsorbed in its absence. Structural integrity is essential and relies heavily on stress forces.^{33,34} In the spine, three main sites encompass the majority of the application of graft material to promote fusion: interbody, intertransverse, and interlaminar. Although dependent on operative technique, number of levels fused, and various risk factors at play, similar and relatively satisfactory fusion rates have been reported in the anterior column of the spine (interbody fusion techniques) with allograft and autograft.³⁵⁻³⁹ This is not the case in the posterior spine, where tension forces predominate over compressive forces. The posterior column of the spine is also a hostile environment for bone fusion for many other reasons.

No competing interests declared.

Received June 2, 2004; Revised September 16, 2004; Accepted September 23, 2004.

From the Graduate Division, Harvard University, Cambridge, MA (Samartzis), the Graduate Division of Health Sciences, University of Oxford, Oxford, England (Samartzis); Orthopedic Specialists of Northwest Indiana, Munster, IN (Khanna); the Department of Orthopaedic Surgery, University of Virginia, Charlottesville, VA (Shen); and the Department of Orthopaedic Surgery, Rush Medical College, Rush-Presbyterian-St Luke's Medical Center, Chicago, IL (An).

Correspondence address: Howard S An, MD, Department of Orthopaedic Surgery, Rush-Presbyterian-St Luke's Medical Center, 1725 W Harrison St, Suite 1063 POB, Chicago, IL 60612. email: han@ortho4.pro.rpslmc.edu

Abbreviations and Acronyms

ALIF	= anterior lumbar interbody fusion
BMP	= bone morphogenetic protein
OP-1	= osteogenic protein-1
rhBMP	= recombinant bone morphogenetic protein

Such a region has primarily cortical bone, less surface area for fusion, and a submuscular environment. Because of these factors, allograft tends not to fare as well as autograft.^{40,41}

It is worthwhile to categorize the multitude of bone graft options for the sake of simplification. In the first category, there are bone graft extenders. These substances act as scaffolding for bone growth, and they do not have any osteoinductive capacity. The second category is the bone graft enhancer, which, when mixed with autograft, can lead to a higher fusion rate than can autograft alone. Finally, bone graft substitutes exist that can replace autograft.

Attempts at fusion for multilevel spine involvement are also associated with high rates of nonunion and morbidity, increasing the risk of failed spinal fusion.^{14,42-48} As the number of fusion sites increases, the risk of nonunion increases and is largely attributed to increased stress and micromotion across the motion segment. To assist in fusion, instrumentation has been used to enhance fusion rates by preventing micromotion across the motion segment, providing a balanced graft stress exposure to optimize the structural integrity of the graft.^{46,47,49,50} But internal fixation may provide excessive stress shielding or improper load sharing that could result in inappropriate mechanical stress exposure, which could contribute to nonunion, potential instrumentation failure, subsequent morbidities, and increased risk

Table 1. Properties of a Bone Graft That Are Integral to Promoting Spinal Fusion

Process	Activity
Osteogenesis	Cellular properties (osteoprogenitor cells) intrinsic to the graft substrate that aid in the synthesis of new bone at the recipient site
Osteoconduction	The scaffolding capabilities and properties of the graft substrate that can support new bone formation and growth
Osteoinduction	The recruitment and differentiation of host mesenchymal stem cells to induce the formation of new bone via the production of osteoblasts

of reoperation.^{44,45} So even though internal instrumentation in spinal fusion has improved fusion rates somewhat, it has failed to completely eradicate the risk of nonunion. Many alternative graft substrates have been investigated to avoid associated complications, but no substitute has yielded superior or similar results to the gold standard—autograft. To address the growing concern of failed spinal fusions and associated morbidities, the efficacy and feasibility of bone morphogenetic proteins (BMPs) has gained considerable interest and investigation.

Historical perspective

The initial indication for the existence of BMPs was reported in 1917 with the observation that bone growth was evident in surgically implanted fascia to bridge gaps within the bladder.⁵¹ Later, in 1931, Huggins⁵² noted that demineralized bone and transitional urinary epithelium possessed osteoinductive capabilities for connective tissue ectopic bone formation. In 1965, Urist⁵³ isolated bone inductive extract from adult bone and demonstrated the ability of this extract to induce new endochondral bone formation at ectopic sites in a rat model. As a result, Urist identified this extract as bone morphogenetic protein. But because no reproducible assay for this protein was available, Urist could not definitively illustrate its capabilities in inducing new bone formation. It wasn't until the early 1980s that Sampath and Reddi⁵⁴ clearly demonstrated, using an assay based on the activity of calcium and alkaline phosphatase, that the protein and not its matrix was responsible for ectopic bone formation. In the ensuing years, extracted and purified forms of human BMPs have exhibited promise in treatment of nonunions of the tibia,⁵⁵ femur,⁵⁶ and segmental long bone defects.^{57,58} In a landmark decision, the FDA finally approved the use of BMPs (BMP-2 in a collagen carrier) in 2002 for the use of anterior lumbar interbody fusion (ALIF). Through further evaluation of the recombinant DNA technology of the genes responsible for the induction of BMPs and their signaling capabilities toward bone formation, understanding of these bone-forming agents and their application to the spine has further increased.

Molecular biology of BMPs

BMPs are multifunctional cytokines that are members of the TGF- β superfamily proteins, which consist of 43 members. The role of the TGF- β superfamily involves

cell growth, differentiation, and embryonic pattern formation. Currently, approximately 20 BMPs are known, including the addition of various growth/differentiation factors (GDFs) based on sequence homology, that are responsible for inducing ectopic bone formation, chondroblast formation, and visceral development. So BMPs are involved in cell proliferation, differentiation, apoptosis, and morphogenesis. They are broadly divided into three subclasses based on derived amino acid sequences. The first subclass is the BMP-2 and BMP-4. They differ mainly in the amino terminal group. The second subgroup is BMP-5,6, 7(OP-1), and 8(OP-2). These molecules are larger than the first group. The third subgroup is BMP-3 (osteogenin), which is more distantly related.⁵⁹

The function of BMPs is multifaceted. Besides involvement in bone and cartilage formation, BMPs create an environment for red bone marrow formation and contribute to systemic hematopoietic production. Through cooperative signaling in the neural tube, BMPs act as morphogens to induce differentiation of dorsal and intermediate cell types.⁶⁰ Studies have indicated that BMP-2 is involved in the formation of neuronal phenotype by development of the neural crest.⁶¹ BMP-4 has been noted in the development of the dorsal neuromusculature and in the inhibition of the myogenesis process to direct somite development.⁶² BMP-2 and BMP-7 are also involved in the formation of the sympathetic adrenergic phenotype.⁶¹ BMPs are also involved within the CNS to promote astroglial lineage and induce embryonic progenitor cells to maintain regional neuronal survival.^{60,63} The various functions and alternative names for the more common BMP subtypes can be found in Table 2.

Although about 20 BMPs are known, each enjoys specific structural features. In general, BMPs are 30- to 38-kDa homodimers that are synthesized as prepropeptides, consist of roughly 400 to 525 amino acids, and, at maturity, form a cysteine knot with 6 conserved cysteine residues with the possibility of an additional 1 to 3 cysteines. Before secretion, the prosegment length is variably cleaved and forms a dimer with occasional disulfide linkage at mature segments. Also, BMPs vary in N-linked glycosylation sites and present cross-species bioactivity. As such, BMPs are further classified based on their amino acid sequence into the following suggested groups: 1) BMP-2 and BMP-4; 2) BMP-3 and BMP-3b; 3) BMP-5, BMP-6, BMP-7, BMP-8, and BMP-8b (oc-

curs only in mice); 4) BMP-9 and BMP-10; 5) BMP-12, BMP-13, and BMP-14; and 6) BMP-11 and GDF-8 (myostatin).^{60,64,65} But 6 of the 20 isolated BMPs appear to be structurally related in regard to endochondral bone formation.

Receptors are vital in the signal transduction of BMPs. Three transforming growth factor receptors exist: type I, type II, and type III, but type I and type II are the only established receptors that are integral to BMP signaling and binding. These receptors have similarities, but vary in their interaction with various BMPs. Both have serine/threonine kinase receptors and a "creatin box" located in a compact extracellular matrix. In addition, both receptors entail the interaction of various Smad intracellular molecules that play an integral role in the cellular activity of BMP-induced osteoinduction (Fig. 1).⁶⁶⁻⁶⁸ The type of Smad activation is dependent on the type of BMP receptor activated and the type of BMP ligand.

Bone healing

Proper bone repair and graft incorporation are essential for optimal osseous healing. Bone incorporation entails the following stages: inflammation, vascularization, osteoinduction, osteoconduction, and remodeling.⁶⁹ Inflammation initiates the first stage of bone repair and lasts approximately 14 days, with increased duration and quantity seen in allograft as compared with autograft. The vascularization stage follows and is characterized by vascular ingrowth of capillary buds that extend from the host and invade the graft. Interference with this vascular ingrowth stemming from infection, irradiation, dense scar, severe osteopenia, or excessive inflammation may prevent proper healing and graft-host incorporation.⁷⁰ During this stage, sensitivity to donor antigens from the host occurs. Afterward, pluripotential cells differentiate into osteoblasts and represent the third stage, osteoinduction. This stage runs parallel with the vascularization stage and is initiated between days 14 and 21. BMPs further aid in inducing osteoblast formation by acting on perivascular undifferentiated mesenchymal cells. This stage is also characterized by a creeping substitution, in which osteoblasts are deposited in trabeculae where, simultaneously, osteoclasts are involved in bone resorption. The fourth stage, osteointegration, entails passive host ingrowth into the graft and may last for months in cancellous bone or for several years in cortical

Table 2. Subtypes of Bone Morphogenetic Proteins and Their Respective Primary and Common Functions

BMP subtype	Alternative name	Function
BMP-1	—	Not a member of the TGF- β superfamily and not technically a BMP Cleaves procollagens I, II, and III to produce fragments that self-associate into mature collagen fibrils Induces cartilage and bone formation
BMP-2	BMP-2a	Role in cartilage and bone formation during embryogenesis Possible role in morphogenesis Active role in the induction of osteogenesis from lineage-specific differentiation of mesenchymal progenitor cells and in mature osteoblasts Role as apoptotic signal molecule Expressed in lung, spleen, and colon
BMP-3	Osteogenin	Role in cartilage and bone formation Functions as chemoattractant Induces synthesis and secretion of TGF- β -1 by monocytes (certain factors associated with collagen synthesis and associated matrix constituents) Expressed in lung, ovary, and small intestine
BMP-3b	GDF-10	Role in endochondral bone formation in mature animals Expressed in cerebellum, lung, pancreas, testis, and femur
BMP-4	BMP-2b	Regulatory developmental molecule Involved in mesoderm and bone induction, limb formation, fracture repair, and tooth development Role in spinal cord oligodendrogenesis patterning Induces formation of embryonic hematopoietic tissue Expressed in lung and kidneys
BMP-5	—	Role in early developmental skeletal patterning Expressed mainly in lungs and liver
BMP-6	Vgr-1	Role in cartilage and bone formation Active role in the induction of osteoblast lineage-specific differentiation of mesenchymal progenitor cells High concentration found in cartilage of the fetus
BMP-7	OP-1	Role in cartilage and skeletal patterning, lens formation, and acts as an early inducer of glomeruli formation Possible osteoinductive factor for epithelial osteogenesis Role in bone homeostasis and calcium regulation Expressed in brain, kidney, and bladder
BMP-8	BMP-8a, OP-2	Role in the maintenance of spermatogenesis Expressed at high levels during pregnancy in the decidual cells of the uterus
BMP-8b	OP-3	Found only in mice Role in the prevention of male adult germ cell apoptosis Expressed at high levels in the trophoblasts of the placenta
BMP-9	GDF-2	Active role in the induction of osteogenesis from lineage-specific differentiation of mesenchymal progenitor cells and in mature osteoblasts Role in hepatic reticuloendothelial and nervous system Acts as hematopoietic hormone
BMP-10	—	Role in cardiac development (trabeculation of embryonic heart)
BMP-11	GDF-11	Role during embryogenesis in the development of mesodermal and neuronal (dorsal root ganglia and dorsal lateral region of the spinal cord) tissues
BMP-12	GDF-7, CDMP-3	Involved in chondrogenesis Role in tendon/ligament formation and repair
BMP-13	GDF-6, CDMP-2	Involved in chondrogenesis Role in tendon/ligament formation and repair Expressed mainly in long bones during embryonic development
BMP-14	GDF-5, CDMP-1	Involved in chondrogenesis Role as neurotrophic, survival-promoting molecule for dopaminergic neurons Enhances tendon healing and bone formation Expressed mainly in long bones during embryonic development
BMP-15	GDF-9b	Role in ovarian development and function

BMP, bone morphogenetic protein; CDMP, cartilage-derived morphogenetic protein; GDF, growth/differentiation factor; OP, osteogenic protein; Vgr, vegetal related.

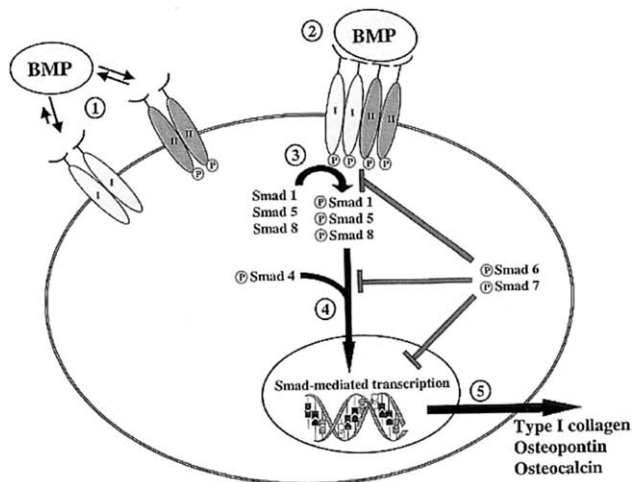


Figure 1. Schematic drawing showing cellular mechanisms of bone morphogenetic protein (BMP)-induced osteoinduction in a mesenchymal bone marrow stem cell. 1, Homodimers of type I and type II BMP receptors exist independently in the cell membrane. Although both receptors have poor affinity for BMP in their native state, type I has better affinity than type II. Type II receptors are constitutively phosphorylated and both types of receptors are serine/threonine kinases. 2, Optimal activation occurs within a complex of BMP, type I, and type II receptors. Complexes of type I and type II receptors have strong affinity for BMP. On activation by BMP, type II receptors transphosphorylate type I receptors. 3, Intracellular messengers (Smads) are phosphorylated into active forms by phosphorylated type I BMP receptors. Depending on the specific BMP ligand and the specific type I BMP receptor, various receptor-Smad proteins are activated. Osteoinduction primarily is signaled by Smads 1, 5, and 8. 4, Activated Smads localize across the nuclear membrane after association with activated Smad-4, a critical cofactor. 5, Once within the nucleus, Smad proteins induce specific gene expression. Different genes are transcribed depending on the species of Smad protein activated. In mesenchymal marrow cells, BMP-2 induces the expression of type I collagen, osteopontin, and osteocalcin. Although the entire feedback process is not yet understood, inhibitory Smads are also activated by phosphorylation. Smads 6 and 7 competitively inhibit the phosphorylation of receptor-Smads, compete for Smad-4, and inhibit Smad-mediated transcription. (Reprinted from Walker DH, Wright NM. Bone morphogenetic proteins and spinal fusion. *Neurosurg Focus* 2002;13:1-13,⁶⁸ with permission. Copyright 2002 American Association of Neurological Surgeons.)

bone. The final stage, remodeling, is initiated and completes within several months to years.

Although autograft bone is considered the gold standard for graft material, differences do exist between cortical and cancellous tissue in regard to incorporation and strength. Usually, the inflammatory stage is the same for both tissue types, but revascularization is slower, usually not complete, occurs along Haversian canals, and bony resorption precedes bony deposition in cortical bone. So the structural strength decreases to half of its initial

proceed at 6 to 8 months after implantation.⁷¹ During this period, necrotic bone deposits also build up, leading to graft failure demanding internal fixation. In comparison, incorporation of cancellous allograft is slower and less complete as compared with autograft. Inflammation is greater and vascularization and osteoinduction are affected because of thrombosed and decreased amounts of vascular budding capillaries. To compensate, BMPs function as a scaffold in fresh-frozen allografts to facilitate bony ingrowth. Cortical allograft also varies from autogenous sources and occurs at a slower, less complete pace, with decreased structural support. Nevertheless, various bone graft substrates do exist and possess varied biomechanical and molecular properties that warrant attention and consideration (Table 3).

Incorporation and sources of BMPs

BMPs have potential to heal fractures, stabilize motion segments, and provide an environment to promote graft-host incorporation. An ideal BMP would induce the formation of osteoblasts and osteocytes from osteoprogenitor cells. Because the precursor cells are limited in an aging spine, increasing the concentration of marrow cell extract is possible but minimal. So the graft substrate would need to promote the production of local growth factors to stimulate osteoinduction. Various factors are also believed to stimulate vascularization and bone growth and are attributed to growth factors and hematoma stemming from the site of injury. The hematoma milieu develops from an inflammatory response produced by localized necrotic tissue deposits. Hematoma is believed to act as an osteogenic agent, capturing cytokines from the necrotic bone.⁷² The graft substrate would also need to provide a proper scaffold for bone ingrowth to facilitate osteoconduction.

The hallmark of BMPs is their ability to enhance osteoinduction. The osteoinductive role of BMPs acts as both a chemotactic agent and a growth and differentiating factor. As a chemotactic agent, BMPs influence migration of progenitor and stem cells to the graft-host interface or injury site. BMPs act as growth factors to stimulate angiogenesis and stem cell proliferation, and, as differentiating factors, they induce the maturation of stem cells into chondrocytes, osteoblasts, and osteocytes.⁷³ So BMPs can start the entire process of bone formation *de novo*. But Cheng and colleagues,⁷⁴ suggested a BMP hierarchical model that addresses the induction of osteoblast differentiation from mesenchymal

Table 3. Properties of Various Bone Graft Substrates

Grafting material	Osteoconduction	Osteoinduction	Osteoprogenitor cells	Immunogenicity	Donor-site morbidity	Immediate torque strength
Cancellous autologous graft	++++	++	+++	-	+	-
Cortical autologous graft	+	+/-	+/-	-	+	++
Fresh allograft	+	+/-	-	++	-	++
Frozen allograft	+	+/-	-	+	-	++
Freeze-dried allograft	+	+/-	-	+/-	-	+
Ceramics	+	+/-	-	-	-	+/-
Demineralized bone matrix	+	-	-	-	-	-
Bone marrow	-	+/-	++	-	-	-
Particulate ceramic with bone marrow	++	+/-	++	-	-	-

+, weak positive role; ++, more positive role; +++, strong positive role; +++++, strongest positive role; -, no role; +/-, may play a role. (Reprinted from Gazdag AR, Lane JM, Glaser D, et al. Alternatives to autogenous bone graft: efficacy and indications. *J Am Acad Orthop Surg* 1995;3:1-8,¹¹⁹ with permission. Copyright 1995 American Academy of Orthopaedic Surgeons.)

stem cells as opposed to just stimulating osteogenesis in mature osteoblasts, which most BMPs are capable of doing. The authors concluded that BMPs-2, -6, and -9 are more capable of inducing osteogenesis from lineage-specific differentiation of mesenchymal progenitor cells than are their BMP counterparts. The authors stated that to optimize bone regeneration, a synergism between BMPs in contrast to sole BMP use may be an aspect to consider increasing osteogenic activity.

Avenues for extracting bone-promoting factors have developed with innovative techniques during the past decade. Currently available sources to obtain osteopromoting and differentiation factors include human or animal bone matrices, recombinant DNA technology, and direct site application of DNA encoding for the desired factor.

As was previously noted, bone-stimulating factors can be obtained from human or animal bone matrices. Isolation of these factors from bovine bone has been investigated since the initial discovery of BMPs by Urist and his colleagues 35 years ago. Presently, such sources are engineered and manufactured for commercial use and implemented with carrier substances, such as hydroxyapatite, collagen, and calcium sulfate.^{75,76} According to previous studies, such sources of BMPs have yielded promising results in bone bridging to address skeletal segmental defects in dogs and in posterolateral spinal fusion in animal models.⁷⁵⁻⁷⁷ Bovine BMP mixture is not readily available commercially and is limited to one source—NeOsteo(Sulzer Orthopaedics Biologics). This commercial mixture undergoes reproducible extraction and has demonstrated osteoinduction.

A second source of BMP is through recombinant technology. The desired structure is identified through bovine protein from bone extracts. Human cDNA sequence is obtained by oligonucleotide probes. Next, the process of recombination ensues; the cDNA clone is spliced into a viral expression vector and transferred into a carrier cell. The product is recombinant BMP (rh-BMP) and may vary in purity. The use of rhBMP has been implemented in animal and human subjects with promising results.

A third method of obtaining bone growth and differentiation factors entails gene therapy and direct delivery of a genetic growth factor to the site of interest to encode for certain desired factors. This method obviates the direct local application of BMPs to the site, but is the most novel method and is still under intense investigation. It is believed that this strategy provides a more prolonged signal for desired osteoinduction, and the production cost of DNA replication is less than the manufacturing of recombinant proteins.

Research

Animal studies

Extracted human BMPs purified from cadaveric bone exist in limited quantities and exhibit variable osteoinductive and biochemical capabilities attributed to individual composition and purity. To address such shortcomings, recombinant techniques to produce BMPs to induce bone formation in vivo have exhibited prowess in various animals models. Experimental work is technical and investigation of these effects is an arduous process, which has led to the identification of six members of the

BMP family through molecular cloning methods involved in bone or cartilage formation. In vivo, BMP-induced osteoblast and chondroblast formation is evident and is extensively explored with rhBMP-2 and, to a lesser degree, with rhBMP-7, also known as osteogenic protein-1 (OP-1).

In 1990, Wang and associates⁷⁸ reported the effects of rhBMP-2 in Chinese hamster ovarian cell lines. The implications of rhBMPs in defects on intramuscular, tibia, and calvarium regions in baboons were reported with promising results.⁷⁹⁻⁸¹ Later, the dose-effect relationship of rhBMP-2 and ectopic bone formation was demonstrated in a rat model to be as much as 10-fold greater than the original bone extract.^{77,82-84} Work published by Sandhu and colleagues^{85,86} in a canine intertransverse fusion model indicated that rhBMP-2 is dose dependent. The study indicated that successful bone fusion was noted by 3 months in the rhBMP-2 specimens, and no fusion was noted in the autograft samples. Boden and coauthors⁸⁷ further supported the notion that increased dosages of rhBMP-2 can yield quicker bone formation. Work in rabbits, sheep, and goats demonstrated a greater amount of fusion and graft stiffness in BMP-treated animals than non-BMP-treated animals.

In order to establish validity and practical clinical applications of BMPs, primate experimental work was sought. Boden and coworkers⁸⁸ investigated the effects of rhBMP-2 in a sponge carrier in a nonhuman primate involving intertransverse spinal fusion, where decortication was performed for fusion. The study illustrated a higher rate of new bone formation and minimal scar formation in the nonhuman primate model with rhBMP-2 compared with control samples. Conversely, Sandhu and associates⁸⁹ demonstrated that intertransverse fusion is obtained with rhBMP-2 without having to decorticate the site to facilitate bone fusion, as is readily performed in spine fusion procedures to establish union. Cook and colleagues⁹⁰ reported on the effects of OP-1 as compared with autograft pertaining to intertransverse spinal fusion in a canine model. The study noted fusion in all animals, but overlapping osteoinductive signaling existed from the concomitant application of both autograft and OP-1 at different levels within the same sample. Paramore and colleagues⁹¹ later reported successful fusion using OP-1 in 10 of 11 dogs by manual palpation and in 7 of 11 dogs by cross-sectional imaging evaluation. Grauer and associates⁹² further elucidated in sheep the efficacy of OP-1 as compared with other graft

substrates, demonstrating a 100% fusion rate in the carrier OP-1 group and 63% and 0% in the autograft and carrier-alone groups, respectively.

Vaccaro and coworkers⁹³ compared OP-1 and autograft alone to achieve noninstrumented posterolateral fusion after decompression in the treatment of patients with degenerative spondylolisthesis. This multicenter study with 12 patients demonstrated OP-1 to be safe, but the fusion rates were not significantly better than in historical controls of autograft alone. In addition, a study by Jenis and associates⁹⁴ evaluated in rabbits the roles of rigid instrumentation and no instrumentation for lumbar posterolateral fusion with autogenous iliac crest bone graft or OP-1. Their findings demonstrated that by 12 weeks, all animals with OP-1 exhibited fusion; no fusion was noted in the autograft group. Also, rigid instrumentation did not seem to affect the fusion rate in the OP-1 animals at 12 weeks, but slightly increased the fusion rate for both groups at 3 weeks. The authors concluded that the application of rigid instrumentation as an adjunct to OP-1 for posterolateral fusion of the lumbar spine may enhance fusion early in the bone-healing process, but may not serve any benefit with regard to fusion rate in the longterm.

Because of the risk of graft collapse, resorption, and subsidence, the role of BMPs in interbody fusion were also addressed. Zdeblick and coworkers⁹⁵ investigated the use of BMPs in goats in anterior cervical interbody fusion procedures. The study demonstrated that interbody cages packed with autograft developed nonunions in three of seven animals; successful fusion was noted in all specimens with a cage filled with a collagen-impregnated rhBMP-2 sponge. The results also indicated that the biomechanical strength of both constructs was equal.

Boden and coauthors⁸⁷ further illustrated the prowess of rhBMP-2 in interbody fusion through a laparoscopic anterior lumbar approach in a nonhuman primate model by using a titanium-threaded interbody cage carrier. Their findings demonstrated a higher fusion rate in rhBMP-2 specimens as compared with autograft. In 2002, Sandhu and colleagues⁹⁶ further illustrated that rhBMP-2 can result in earlier radiographic fusion assessment and enhanced segmental stiffness as compared with autograft in a sheep ALIF model implementing a cylindrical fenestrated titanium interbody fusion device. The study also noted a threefold increase in histologic fusion rate and a decrease in fibrous tissue encompassing

the implant in rhBMP-2 specimens in comparison to the autograft group. Studies have demonstrated that a greater histologic ossification, irrespective of vascularity at the graft-host interface, has been noted in lumbar interbody fusion with the use of OP-1 as compared with autograft.^{78,97-99}

Nicotine use is a well-documented systemic factor that compromises bone healing in spinal fusion and increases the potential for nonunion.^{10,15,18,100} Bone remodeling and incorporation require the vascular ingrowth of mesenchymal cells into the graft substrate for osteoblast and osteoclast differentiation. Cigarette smoking inhibits appropriate vascular ingrowth to the graft substrate in order to promote osteoblast cellular metabolism, preventing osteoblast proliferation and ensuing collagen synthesis for scaffold formation.^{7-9,14} It has been suggested that nicotine causes circulatory occlusion to the bone-host interface because of an increase in blood viscosity to bone, which could lead to impaired bone growth.^{6,12,13,16} To address the concern of improper bone healing from exposure to smoking and its nicotinic content, Silcox and associates¹⁰¹ implemented bovine-derived osteoinductive bone protein extracts to evaluate the inhibitory effect of posterolateral lumbar spinal fusion in a rabbit model. The study demonstrated that osteoinductive bone protein coupled with autogenous bone graft yielded a 100% fusion rate in the presence of nicotine. Conversely, autograft alone and osteoinductive bone protein plus demineralized bone matrix demonstrated 0% and 64% fusion rates, respectively. In the absence of nicotine exposure in a rabbit model, OP-1 demonstrated a 100% fusion rate in posterolateral fusion.⁹² Using a rabbit posterolateral spine fusion model in the presence of nicotine exposure, Patel and coworkers¹⁰² demonstrated a 25% fusion rate using autograft and a 100% fusion rate in samples with OP-1.

A significant focus of research on BMP has been on developing an ideal carrier. McKay and Sandhu¹⁰³ summarized three important functions of the carrier. First, the carrier should act as three-dimensional space scaffolding across which de novo bone formation can occur. Also, the carrier should maintain a certain effective threshold concentration of BMP. Third, the carrier should be able to contain the BMP and not allow for extraneous bone formation. So the carrier should be a resorbable substrate that has a resorption rate that matches bone formation. To date, no effective structural carrier for BMP has been identified. The collagen

sponge has been shown to be an effective carrier for BMP in multiple studies. In order to provide a structural support for anterior interbody fusion, the collagen sponge has been housed in a variety of structural titanium cages.^{87,95} Hecht and coauthors¹⁰⁴ conducted a study evaluating the use of allograft structural dowels in combination with rhBMP-2 in a rhesus monkey model. The allograft with rhBMP-2 had undergone complete resorption and remodeling during the fusion period. This implied a much larger role for the rhBMP-2 than just osteoblastic activity.

The collagen sponge has not worked as an effective carrier in posterior intertransverse process fusion in primates. Martin and associates⁸⁴ demonstrated that the dose used in lower animals was insufficient to allow for bone growth in nonhuman primates. The hypothesis was that compression of the collagen sponge from the local muscles inhibited bone formation. When the compression of the collagen sponge was eliminated by a polyethylene protector, bone fusion was noted. Boden and coauthors¹⁰⁵ studied a carrier made of a highly porous biphasic calcium phosphate ceramic. This carrier was able to produce a solid fusion in a primate model regardless of the dosage tested. Evaluation of a compression-resistant matrix to help shield the rhBMP carrier from compression and ease radiographic visualization of new bone has been performed with promising results entailing biphasic calcium phosphate granules or allograft bone chips to the collagen sponge for posterolateral fusion in monkeys.¹⁰⁶

Human studies

Human BMP studies are limited, but promising. Boden and colleagues¹⁰⁷ reported their experience in a prospective clinical and radiographic study with 14 human subjects who underwent a single-level ALIF with a threaded titanium cage. All patients who received cage-filled rhBMP-2 demonstrated successful fusion as compared with 66% success in the cage-filled autograft control group. The rhBMP-2 group indicated improved functional scores sooner than did the autograft group. Gornet and colleagues¹⁰⁸ reported their prospective findings in human subjects of rhBMP-2 in conjunction with tapered metal fusion cages compared with cages packed with autograft. At 24 months postoperatively, the rhBMP-2 group achieved a fusion rate of 94.5% compared with the 88.7% fusion rate in the autograft group. The study also noted fusion for all patients with

rhBMP-2 at 6 months. Average operative time, blood loss, and hospital stay were less than in the autograft group. Autograft patients reported considerable donor-site pain compared with no pain for patients who underwent rhBMP-2 application.

Burkus and associates¹⁰⁹ presented a multicenter, prospective, randomized, controlled trial of single-level open ALIF comparing patients with threaded cortical allograft dowels and rhBMP-2 (investigational group) with patients who received threaded allograft dowels with iliac crest autogenous bone (control group). The study showed that the investigational group achieved a higher rate of fusion at 1 and 2 years than did the control group. This study also demonstrated persistent donor-site pain 2 years after operation in a high proportion of the controlled group patients. Burkus and coauthors¹¹⁰ also reported the results of a multicenter, prospective, randomized, nonblinded, controlled 2-year study of patients undergoing an ALIF with a tapered titanium cage; 143 patients received rhBMP-2 on an absorbable collagen sponge compared with 136 patients who got iliac crest autogenous bone. Operative time and blood loss were less in the rhBMP-2 group. At 24 months, fusion rates were 94.5% and 88.7% for the rhBMP-2 and autograft groups, respectively. Similar clinical outcomes measurements were noted in both groups, but at 24 months, 32% of patients reported graft site-related complications. Alexander and coworkers¹¹¹ described the use of rhBMP-2 with a posterior lumbar interbody fusion approach. The cages were cylindrical hollow-threaded cages used as stand-alone devices. The study had 36 patients in the control autograft group and 35 patients in the BMP group. The fusion rate was lower in the BMP group. In addition, bone formation was noted in the insertion tract of the device. There were no reported neurologic sequelae, though. This concern has stopped this study.

With respect to the cervical spine, Baskin and colleagues,¹¹² in a prospective, randomized trial, evaluated 33 patients who underwent instrumented anterior cervical discectomy and fusion and received either fibular allograft with rhBMP-2-laden collagen carrier inside the graft or fibular allograft with internal iliac crest autologous bone. Although there was no difference in fusion rates between these two groups, the rhBMP group reported superior neck disability and arm pain scores.

Boden and associates¹¹³ reported on the use of rhBMP-2 in human subjects to attain posterolateral fu-

sion. Twenty-five patients were enrolled in the study and divided into three groups. Group I patients had autograft and Texas Scottish Rite Hospital (TSRH) instrumentation, Group II had rhBMP-2 and TSRH instrumentation, and Group III had rhBMP-2 alone without instrumentation. This study used both radiographs and CT scan to determine fusion. Both of the rhBMP-2 groups showed good bone formation in the posterolateral lumbar spine. Johnsson and coworkers¹¹⁴ reported no improved fusion rates with OP-1 versus autograft in noninstrumented posterolateral fusion at the L5-S1 level. But overall, early human trials indicated that rhBMPs enhance fusion rate and avoid morbidities and complications associated with autograft and allograft.

The role of gene therapy is also an exciting frontier. There has been a surge of new studies demonstrating the ability of gene transfection to upregulate the expression of BMPs. Hidaka and colleagues¹¹⁵ demonstrated enhanced spine fusion in rats with adenovirus vector encoding for BMP-7. Riew and coauthors¹¹⁶ reported on a thoracoscopic intradiscal spine fusion in a pig model using adenovirus BMP-2 transduced mesenchymal stem cells. The study had six discs that were treated and six discs that had sham operations. All six discs that were treated showed histologic bridging bone from endplate to endplate at 6 weeks.

Safety considerations

The safety profile must be determined before considering any new technology. Concerns for bone overgrowth and subsequent potential neural compression have stopped the pilot study using BMP for a posterior lumbar interbody fusion/transforaminal lumbar interbody fusion approach. No study has demonstrated any clinically significant neural compression to date. The use of a BMP in postlaminectomy patients for intertransverse spine fusion also raises concern for potential restenosis. Martin and coworkers⁸⁴ showed some bone overgrowth at the laminectomy site in rhesus monkeys undergoing decompression and posterolateral fusion. This has not been demonstrated in human trials but remains a theoretic risk. The fusion of unintended adjacent levels during spine fusion has also been studied. It has been shown that if the substrate is contained within the carrier, bony overgrowth does not occur.¹¹⁷

Different tumors have shown the ability to produce BMP and some have BMP receptors.¹¹⁸ This has caused some concern that BMP possibly has a prooncogenic

effect. There is no animal or human evidence that BMPs are carcinogenic. There are multiple different lines of proteins other than BMPs that are upregulated by tumor cells, and tumor cells demonstrate many different types of receptors.

In conclusion, the spine is a complex system whose treatment modalities have evolved tremendously within the past 30 to 40 years. Spinal fusion has enjoyed wide acceptance, regardless of potential risks and complications involved. As the understanding of the molecular basis of bone biology increases and the technical aspects of bone tissue engineering are advanced, a plethora of common and complex spine problems can be treated by such technologic innovations to improve postoperative outcomes and enhance the patient's quality of life.

The use of BMPs for spine surgery remains promising. BMPs are proved to be osteoinductive in anterior and posterior fusion models, but the exact indications can't be delineated until studies are designed to determine effectiveness, reproducibility, comorbidities, risk factors, and cost-benefit. At this time, it has not been determined which carriers are ideal with BMPs. Also, in certain cases, if BMPs are used, there is a potential to actually diminish fusion rates and, in certain cases, to "overkill" and increase costs without clinical advantages. It is also somewhat difficult to determine the efficacy of BMPs because not all nonunions are symptomatic. Even though it is generally believed that a higher fusion rate is associated with a higher clinical success rate, this has not been conclusively shown in the literature. In addition, how BMPs will compare with demineralized bone matrix, which is also composed to some degree with BMPs, in terms of effectiveness and cost is not known and should be evaluated. Nonetheless, increasing osteoinduction factors will lead to enhanced bone fusion and augmentation of surgical techniques, with an inclination toward minimally invasive procedures and decreased or altered use of internal instrumentation.

REFERENCES

1. Albee F. Transplantation of a portion of the tibia into the spine for Pott's disease. *JAMA* 1911;57:885-886.
2. Hibbs R. An operation for progressive spinal deformities. A preliminary report of three cases from the service of the Orthopaedic Hospital. *NY State J Med* 1911;93:1013-1016.
3. Burchardt H. Biology of bone transplantation. *Orthop Clin North Am* 1987;18:187-196.
4. Damien C, Parsons J. Bone graft and bone graft substitutes: A review of current technology and applications. *J Appl Biomater* 1991;2:187-208.
5. Prolo D, Rodrigo J. Contemporary bone graft physiology and surgery. *Clin Orthop* 1985;200:322-342.
6. Brinkler MR, Lippston HL, Cook SK, et al. Pharmacologic regulation of the circulation of bone. *J Bone Joint Surg [Am]* 1990;72:964-975.
7. Broulik PD, Jarab J. The effect of chronic nicotine administration on bone mineral content in mice. *Horm Metab Res* 1993;25:219-221.
8. Ducker TB. Cigarette smoking and the prevalence of spinal procedures. *J Spinal Disord* 1992;5:134-136.
9. Fang MA, Frost PJ, Iida-Klein A, et al. Effects of nicotine on cellular function in UMR 106-01 osteoblast-like cells. *Bone* 1991;12:283-286.
10. Glassman SD, Anagnost SC, Parker A, et al. The effect of cigarette smoking and smoking cessation on spinal fusion. *Spine* 2000;15:2608-2615.
11. Glassman SD, Rose SM, Dimar JR, et al. The effect of postoperative nonsteroidal anti-inflammatory drug administration on spinal fusion. *Spine* 1998;23:834-838.
12. Hambly ME, Mooney V. Effect of smoking and pulsed electromagnetic fields on intradiscal pH in rabbits. *Spine* 1992;16 [Suppl]:83-85.
13. Noronha-Dutra AA, Epperlein MM, Woolf N. Effect of cigarette smoking on cultured endothelial cells. *Cardiovasc Res* 1993;27:774-778.
14. Phillips FM, Carlson G, Emery S, et al. Anterior cervical pseudoarthrosis. *Spine* 1997;22:1585-1589.
15. Silcox DHR, Daftari T, Boden SD, et al. The effect of nicotine on spinal fusion. *Spine* 1995;20:1549-1553.
16. Sonnenfeld T, Wenmalm A. Inhibition of nicotine on the formation of prostacyclin like activity in rabbit and human vascular tissue. *Br J Pharm* 1980;71:609-613.
17. Theiss SM, Boden SD, Hair GA, et al. The effect of nicotine on gene expression during spinal fusion. *Spine* 2000;25:2588-2594.
18. Wing KJ, Fisher CG, O'Connell JX, et al. Stopping nicotine exposure before surgery. The effect on spinal fusion in a rabbit model. *Spine* 2000;25:30-34.
19. Boden SD. Overview of the biology of lumbar spine fusion and principles for selecting a bone graft substitute. *Spine* 2002;27:S26-31.
20. DePalma AF, Rothman R, Lewinneck G, et al. Anterior interbody fusion for cervical disc degeneration. *Surg Gynecol Obstet* 1972;134:755-758.
21. Guha SC, Poole MD. Stress fracture of the iliac bone with subfascial femoral neuropathy: Unusual complications at a bone graft donor site. *Br J Plast Surg* 1983;36:305-306.
22. Hu RW, Bohlman HH. Fracture at the iliac crest bone graft harvest site after fusion of the spine. *Clin Orthop* 1994;309:208-213.
23. Schnee CL, Freese A, Weil RJ, et al. Analysis of harvest morbidity and radiographic outcome using autograft for anterior cervical fusion. *Spine* 1997;22:2222-2226.
24. Summers BN, Eisenstein SM. Donor site pain from the ilium: A complication of the lumbar spine fusion. *J Bone Joint Surg* 1989;71B:667-680.
25. Whitecloud TS. Complications of anterior cervical fusion. *Instr Course Lect* 1976;27:223-227.
26. Steinman JC, Herkowitz HN. Pseudarthrosis of the spine. *Curr Ortho Rel Res* 1992;284:80-90.

27. Zdeblick TA. A prospective, randomized study of lumbar fusion. *Spine* 1993;18:983-991.
28. Buck B, Malinin T, Brown M. Bone transplantation and human immunodeficiency virus. *Clin Orthop* 1989;240:129-136.
29. Burchardt H, Enneking W. Transplantation of bone. *Surg Clin North Am* 1978;58:403-427.
30. Centers for Disease Control. Transmission of HIV through bone transplantation. *JAMA* 1988;260:2487-2488.
31. Flatley T, Lynch K, Benson M. Tissue response to implants of calcium phosphate ceramic in the rabbit spine. *Clin Orthop* 1983;179:246-252.
32. Kalfas I. Principles of bone healing. *Neurosurg Focus* 2001;10: Article 1.
33. Wolff J. *Das gesetz der transformation de knochen*. [monograph.] Berlin: Hirshwald 1892.
34. Recker RR. Embryology, anatomy, and microstructure of bone. In: Coe FL, Favus MJ, eds. *Disorders of bone and mineral metabolism*. New York: Raven; 1992:219-240.
35. Bishop RC, Moore KA, Hadley MN. Anterior cervical interbody fusion using autogeneic and allogeneic bone graft substrate: a prospective comparative analysis. *J Neurosurg* 1996;85:206-210.
36. Cauthen JC, Kinard RE, Vogler JB, et al. Outcome analysis of noninstrumented anterior cervical discectomy and interbody fusion in 348 patients. *Spine* 1998;23:188-192.
37. Samartzis D, Shen H, Matthews D, et al. Comparison of allograft to autograft in multilevel anterior cervical discectomy and fusion with rigid plate fixation. *Spine J* 2003;3:451-459.
38. Samartzis D, Shen FH, Goldberg EJ, et al. Is autograft the gold standard in achieving radiographic fusion in one-level anterior cervical discectomy and fusion with rigid anterior plate fixation? *Spine* 2004 (In Press).
39. Wimmer C, Krismer M, Gluch H, et al. Autogenic versus allogenic bone grafts in anterior lumbar interbody fusion. *Clin Orthop* 1999;360:122-126.
40. Jorgenson S, Lowe T, France J, et al. A prospective analysis of autograft in posterolateral lumbar fusion in the same patient: A minimum of 1 year follow-up in 144 patients. *Spine* 1994;19:2048-2053.
41. Malinin T, Brown M. Bone allografts in spinal surgery. *Clin Orthop* 1981;154:68-73.
42. An HS, Simpson JM, Glover JM, et al. Comparison between allograft plus demineralized bone matrix versus autograft in anterior cervical fusion. A prospective multicenter study. *Spine* 1995;15:2211-2216.
43. Emery SE, Fisher JR, Bohlman HH. Three-level anterior cervical discectomy and fusion: radiographic and clinical results. *Spine* 1997;22:2622-2624; discussion 2625.
44. Lowery GL, McDonough RF. The significance of hardware failure in anterior cervical plate fixation. Patients with 2- to 7-year follow-up. *Spine* 1998;23:181-186; discussion 186-187.
45. Paramore CG, Dickman CA, Sonntag VK. Radiographic and clinical follow-up review of Caspar plates in 49 patients. *J Neurosurg* 1996;84:957-961.
46. Wang JC, McDonough PW, Endow KK, et al. Increased fusion rates with cervical plating for two-level anterior cervical discectomy and fusion. *Spine* 2000;25:41-45.
47. Wang JC, McDonough PW, Kanim LEA, et al. Increased fusion rates with cervical plating for three-level anterior cervical discectomy and fusion. *Spine* 2001;26:643-647.
48. Zdeblick T, Ducker TB. The use of freeze-dried allograft bone for anterior cervical fusions. *Spine* 1991;16:726-729.
49. Bolesta MJ, Rehtine GR, Chrin AM. Three- and four-level anterior cervical discectomy and fusion with plate fixation: a prospective study. *Spine* 2000;25:2040-2044.
50. Bose B. Anterior cervical instrumentation enhances fusion rates in multilevel reconstruction in smokers. *J Spinal Disord* 2001;14:3-9.
51. Neuhof H. *Surg Gynec Obst* 1917;24:383.
52. Huggins C. *Arch Surg* 1931;22:377.
53. Urist M. Bone formation by autoinduction. *Science* 1965;150:893-899.
54. Sampath TK, Reddi AH. Dissociative extraction and reconstitution of extracellular matrix components involved in local bone differentiation. *Proc Natl Acad Sci USA* 1981;78:7599-7603.
55. Johnson EE, Urist MR, Finerman GAM. Distal metaphyseal tibial nonunion: Deformity and bone loss treated by open reduction, internal fixation, and human bone morphogenetic protein (hBMP). *Clin Orthop* 1990;250:234-240.
56. Johnson EE, Urist MR, Finerman GAM. Bone morphogenetic protein augmentation grafting of resistant femoral nonunions: A preliminary report. *Clin Orthop* 1988;230:257-265.
57. Johnson EE, Urist MR, Finerman GAM. Repair of segmental defects of the tibia with cancellous bone grafts augmented with human bone morphogenetic protein: A preliminary report. *Clin Orthop* 1988;236:249-257.
58. Johnson EE, Urist MR, Finerman GAM. Resistant nonunions and partial or complete segmental defects of long bones: Treatment with implants of a composite of human bone morphogenetic protein (BMP) and autolyzed, antigen-extracted, allogeneic (AAA) bone. *Clin Orthop* 1992;277:229-237.
59. Wozney JM, Rosen V. Bone morphogenetic protein and bone morphogenetic protein gene family in bone formation and repair. *Clin Orthop* 1998:26-37.
60. Mehler MF, Mabie PC, Zhang D, et al. Bone morphogenetic proteins in the nervous system. *Trends Neurosci* 1997;20:309-317.
61. Moses HL, Serra R. Regulation of differentiation by TGF-beta. *Curr Opin Genet Dev* 1996;6:581-586.
62. Tajbakhsh S, Cossu G. Establishing myogenic identity during somitogenesis. *Curr Opin Genet Dev* 1997;7:634-641.
63. Ebendal T, Bengtsson H, Soderstrom S. Bone morphogenetic proteins and their receptors: potential functions in the brain. *J Neurosci Res* 1998;51:139-146.
64. Hogan BL. Bone morphogenetic proteins: multifunctional regulators of vertebrate development. *Genes Dev* 1996;10:1580-1594.
65. Yamashita H, Dijke P, Heldin CH, et al. Bone morphogenetic protein receptors. *Bone* 1996;19:569-574.
66. Heldin CH, Miyazono K, ten Dijke P. TGF-beta signaling from cell membrane to nucleus through SMAD proteins. *Nature* 1997;390:465-471.
67. Hoffmann A, Gross G. BMP signaling pathways in cartilage and bone formation. *Crit Rev Eukaryot Gene Expr* 2001;11:23-45.
68. Walker DH, Wright NM. Bone morphogenetic proteins and spinal fusion. *Neurosurg Focus* 2002;13:Article 3.
69. Subach BR, Haid RW, Rodts GE, et al. Bone morphogenetic protein in spinal fusion: overview and clinical update. *Neurosurg Focus* 2001;10:Article 3.

70. Ehrler DM, Vaccaro AR. The use of allograft bone in lumbar spine surgery. *Clin Orthop* 2000;371:38–45.
71. Bos GD, Goldber VM, Powell AE, et al. The effect of histocompatibility matching on canine frozen allografts. *J Bone Joint Surg* 1983;65A:89–96.
72. Mizuno K, Mineo K, Tachibana T, et al. The osteogenic potential of fracture haematoma: Subperiosteal and intramuscular transplantation of the haematoma. *J Bone Joint Surg [Br]* 1990;72:822–829.
73. Boden SD, Sumner DR. Biologic factors affecting spinal fusion and bone regeneration. *Spine* 1995;245:1025–1125.
74. Cheng H, Jiang W, Phillips FM, et al. Osteogenic activity of the fourteen types of human bone morphogenetic proteins (BMPs). *J Bone Joint Surg [Am]* 2003;85A:1544–1552.
75. Damien C, Christel PS, Benedict JJ, et al. A composite of natural coral, collagen, bone protein and basic fibroblast growth factor tested in a rat subcutaneous model. *Ann Chir Gynaecol* 1993; [Suppl 207]:117–128.
76. Damien CJ, Parsons JR, Benedict JJ, et al. Investigation of a hydroxyapatite and calcium sulfate composite supplemented with an osteoinductive factor. *J Biomed Mater Res* 1990;24:639–654.
77. Boden SD, Schimandle JH, Hutton WC. 1995 Volvo Award in basic sciences. The use of an osteoinductive growth factor for lumbar fusion. Part II: study of dose, carrier, and species. *Spine* 1995;20:2633–2644.
78. Wang EA, Rosen V, D'Alessandro JS, et al. Recombinant human bone morphogenetic protein induces bone formation. *Proc Natl Acad Sci USA* 1990;87:2220–2224.
79. Ripamonti U. Bone induction in nonhuman primates: An experimental study on the baboon. *Clin Orthop* 1991;269:284–294.
80. Ripamonti U. Calvarial regeneration in primate with autolyzed antigen-extracted allogeneic bone. *Clin Orthop* 1992;282:293–303.
81. Ripamonti U, Ma S, Reddi AH. Induction of bone in composites of osteogenin and porous hydroxyapatite in baboons. *Plast Reconstr Surg* 1992;89:731–739.
82. Aspenberg P, Turek T. BMP-2 for intramuscular bone induction: effect in squirrel monkeys is dependent on implantation site. *Acta Orthop Scand* 1996;67:3–6.
83. Boden SD, Schimandle JH, Hutton WC. Lumbar intertransverse-process spinal arthrodesis using a bovine bone-derived osteoinductive protein. *J Bone Joint Surg* 1995;77:1404–1417.
84. Martin GJ Jr, Boden SD, Marone MA, et al. Posterolateral intertransverse process spinal arthrodesis with rhBMP-2 in a nonhuman primate: important lessons learned regarding dose, carrier, and safety. *J Spinal Disord* 1999;12:179–186.
85. Sandhu HS, Kanim LE, Kabo JM, et al. Evaluation of rhBMP-2 with an OPLA carrier in a canine posterolateral (transverse process) spinal fusion model. *Spine* 1995;20:2669–2682.
86. Sandhu HS, Kanim LE, Kabo JM, et al. Effective doses of recombinant human bone morphogenetic protein-2 in experimental spinal fusion. *Spine* 1996;21:2115–2122.
87. Boden SD, Martin GJ Jr, Horton WC, et al. Laparoscopic anterior spinal arthrodesis with rhBMP-2 in a titanium interbody threaded cage. *J Spinal Disord* 1998;11:95–101.
88. Boden SD, Moskovitz PA, Morone MA, et al. Video-assisted lateral intertransverse process arthrodesis. Validation of a new minimally invasive lumbar spinal fusion technique in the rabbit and nonhuman primate (rhesus) models. *Spine* 1996;21:2689–2697.
89. Sandhu HS, Kanim LE, Toth JM, et al. Experimental spinal fusion with recombinant human bone morphogenetic protein-2 without decortication of osseous elements. *Spine* 1997;22:1171–1180.
90. Cook SD, Dalton JE, Tan EH, et al. In vivo evaluation of recombinant human osteogenic protein (rhOP-1) implants as a bone graft substitute for spinal fusions. *Spine* 1994;19:1655–1663.
91. Paramore CG, Laurusyssen C, Rauzzino MJ, et al. The safety of OP-1 for lumbar fusion with decompression—a canine study. *Neurosurgery* 1999;44:1151–1155; discussion 1155–1156.
92. Grauer JN, Patel TC, Erulkar JS, et al. 2000 Young Investigator Research Award winner. Evaluation of OP-1 as a graft substitute for intertransverse process lumbar fusion. *Spine* 2001;26:127–133.
93. Vaccaro AR, Patel T, Fischgrund J, et al. A pilot safety and efficacy study of OP-1 putty (rhBMP-7) as an adjunct to iliac crest autograft in posterolateral lumbar fusions. *Eur Spine J* 2003;12:495–500.
94. Jenis LG, Wheeler D, Parazin SJ, et al. The effect of osteogenic protein-1 in instrumented and noninstrumented posterolateral fusion in rabbits. *Spine J* 2002;2:173–178.
95. Zdeblick TA, Ghanayem AJ, Rapoff AJ, et al. Cervical interbody fusion cages. An animal model with and without bone morphogenetic protein. *Spine* 1998;23:758–765; discussion 766.
96. Sandhu HS, Toth JM, Diwan AD, et al. Histologic evaluation of the efficacy of rhBMP-2 compared with autograft bone in sheep spinal anterior interbody fusion. *Spine* 2002;27:567–575.
97. Blattner TR, Delling G, Dalal PS, et al. Successful transpedicular lumbar interbody fusion by means of a composite of osteogenic protein-1 (rhBMP-7) and hydroxyapatite carrier: a comparison with autograft and hydroxyapatite in the sheep spine. *Spine* 2002;27:2697–2705.
98. Cunningham BW, Kanayama M, Parker LM, et al. Osteogenic protein (rhOP-1) versus autologous interbody arthrodesis in the sheep thoracic spine. *Spine* 1999;24:509–518.
99. Magin MN, Delling G. Improved lumbar vertebral interbody fusion using rhOP-1: a comparison of autogenous bone graft, bovine hydroxylapatite (Bio-Oss), and BMP-7 (rhOP-1) in sheep. *Spine* 2001;26:469–478.
100. Theiss SM, Boden SD, Hair G, et al. The effect of nicotine on gene expression during spine fusion. *Spine* 2000;25:2588–2594.
101. Silcox DH 3rd, Boden SD, Schimandle JH, et al. Reversing the inhibitory effect of nicotine on spinal fusion using an osteoinductive protein extract. *Spine* 1998;23:291–296.
102. Patel TC, Erulkar JS, Grauer JN, et al. Osteogenic protein-1 overcomes the inhibitory effect of nicotine on posterolateral lumbar fusion. *Spine* 2001;26:1656–1661.
103. McKay B, Sandhu HS. Use of recombinant human bone morphogenetic protein-2 in spinal fusion applications. *Spine* 2002;27:S66–S85.
104. Hecht BP, Fischgrund JS, Herkowitz HN, et al. The use of recombinant human bone morphogenetic protein 2 (rhBMP-2) to promote spinal fusion in a nonhuman primate anterior interbody fusion model. *Spine* 1999;24:629–636.
105. Boden SD, Martin GJ Jr, Morone MA, et al. Posterolateral lumbar intertransverse process spine arthrodesis with recombi-

- nant human bone morphogenetic protein 2/hydroxyapatite-tricalcium phosphate after laminectomy in the nonhuman primate. *Spine* 1999;24:1179–1185.
106. Akamaru T, Suh D, Boden SD, et al. Simple carrier matrix modifications can enhance delivery of recombinant human bone morphogenetic protein-2 for posterolateral spine fusion. *Spine* 2003;28:429–434.
 107. Boden SD, Zdeblick TA, Sandhu HS, et al. The use of rhBMP-2 in interbody fusion cages. Definitive evidence of osteoinduction in humans: a preliminary report. *Spine* 2000;25:376–381.
 108. Gornet MF, Burkus JK, Dickman CA, et al. rhBMP-2 with tapered cages: a prospective, randomized lumbar fusion study. North American Spine Society 16th Annual Meeting, Seattle, WA, 2001.
 109. Burkus JK, Transfeldt EE, Kitchel SH, et al. Clinical and radiographic outcomes of anterior lumbar interbody fusion using recombinant human bone morphogenetic protein-2. *Spine* 2002;27:2396–2408.
 110. Burkus JK, Gornet MF, Dickman CA, et al. Anterior lumbar interbody fusion using rhBMP-2 with tapered interbody cages. *J Spinal Disord Tech* 2002;15:337–349.
 111. Alexander JT, Branch CL, Haid RW, et al. An analysis of the use of rhBMP-2 in PLIF constructs: clinical and radiographic outcomes. 18th Annual Meeting of the Americal Association of Neurological Surgeons, Chicago, IL, 2002.
 112. Baskin DS, Ryan P, Sonntag V, et al. A prospective, randomized, controlled cervical fusion study using recombinant human bone morphogenetic protein-2 with the CORNERSTONE-SR allograft ring and the ATLANTIS anterior cervical plate. *Spine* 2003;28:1219–1225.
 113. Boden SD, Kang J, Sandhu H, et al. Use of recombinant human bone morphogenetic protein-2 to achieve posterolateral lumbar spine fusion in humans: a prospective, randomized clinical pilot trial: 2002 Volvo Award in clinical studies. *Spine* 2002;27:2662–2673.
 114. Johnsson R, Stromqvist B, Aspenberg P. Randomized radiostereometric study comparing osteogenic protein-1 (BMP-7) and autograft bone in human noninstrumented posterolateral lumbar fusion: 2002 Volvo Award in clinical studies. *Spine* 2002;27:2654–2661.
 115. Hidaka C, Goshi K, Rawlins B, et al. Enhancement of spine fusion using combined gene therapy and tissue engineering BMP-7-expressing bone marrow cells and allograft bone. *Spine* 2003;28:2049–2057.
 116. Riew KD, Lou J, Wright NM, et al. Thoracoscopic intradiscal spine fusion using a minimally invasive gene-therapy technique. *J Bone Joint Surg Am* 2003;85A:866–871.
 117. Poynton AR, Lane JM. Safety profile for the clinical use of bone morphogenetic proteins in the spine. *Spine* 2002;27:S40–48.
 118. Gobbi G, Sangiorgi L, Lenzi L, et al. Seven BMPs and all their receptors are simultaneously expressed in osteosarcoma cells. *Int J Oncol* 2002;20:143–147.
 119. Gazdag AR, Lane JM, Glaser D, et al. Alternatives to autogenous bone graft: efficacy and indications. *J Am Acad Orthop Surg* 1995;3:1–8.

ANNOUNCEMENT

JANUARY 2005

**All manuscripts will be submitted on
the electronic system ONLY.**

**SEE GUIDELINES ON
www.jacs.org**

JACS ONLINE CME-1 PROGRAM

CME-1 COURSE EVERY MONTH

2 CREDITS AVAILABLE EACH MONTH

**48 CREDITS AVAILABLE
AT ALL TIMES**

www.jacsme.facs.org